

**A CLINICAL TREATISE
ON DISEASES OF THE
LIVER, VOL. III**

Published @ 2017 Trieste Publishing Pty Ltd

ISBN 9780649276943

A clinical treatise on diseases of the liver, Vol. III by Fried. Theod. Frerichs

Except for use in any review, the reproduction or utilisation of this work in whole or in part in any form by any electronic, mechanical or other means, now known or hereafter invented, including xerography, photocopying and recording, or in any information storage or retrieval system, is forbidden without the permission of the publisher, Trieste Publishing Pty Ltd, PO Box 1576 Collingwood, Victoria 3066 Australia.

All rights reserved.

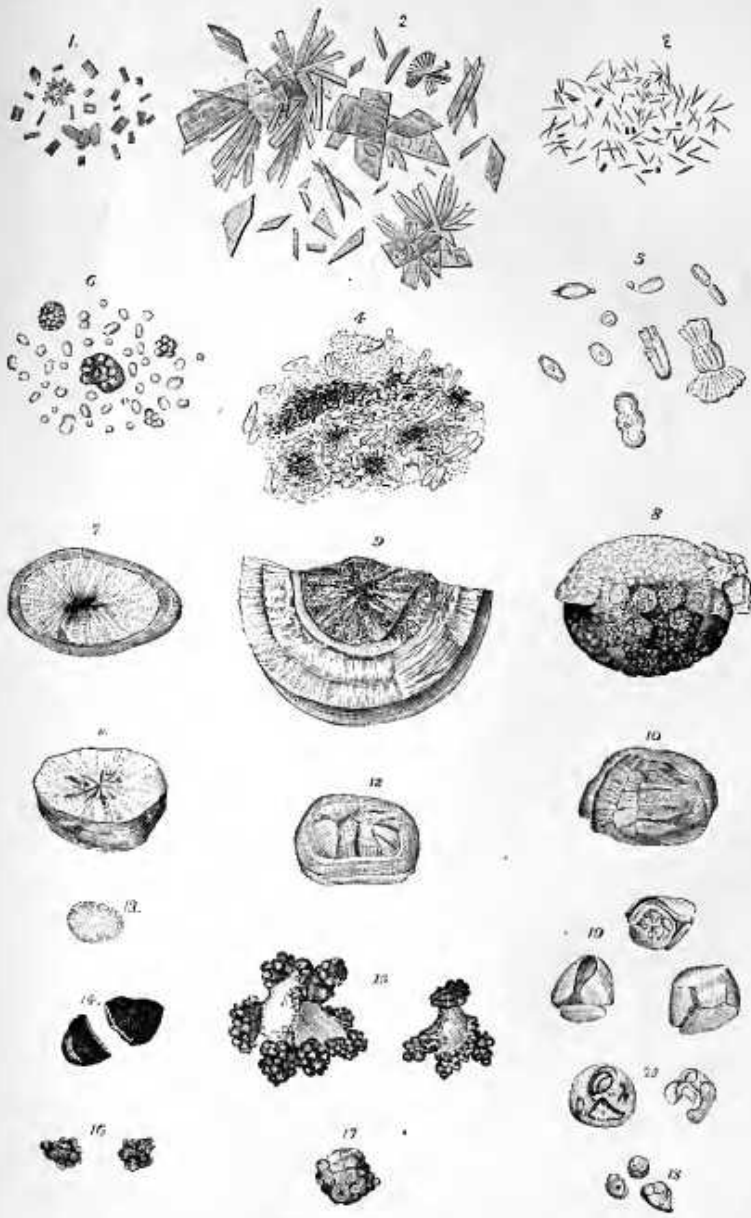
Edited by Trieste Publishing Pty Ltd.
Cover @ 2017

This book is sold subject to the condition that it shall not, by way of trade or otherwise, be lent, re-sold, hired out, or otherwise circulated without the publisher's prior consent in any form or binding or cover other than that in which it is published and without a similar condition including this condition being imposed on the subsequent purchaser.

www.triestepublishing.com

FRIED. THEOD. FRERICHS

**A CLINICAL TREATISE
ON DISEASES OF THE
LIVER, VOL. III**



A
CLINICAL TREATISE
ON
DISEASES OF THE LIVER.

BY
DR. FRIED. THEOD. FRERICHS,
PROFESSOR OF CLINICAL MEDICINE IN THE UNIVERSITY OF BERLIN, ETC.;
MEDICAL PRIVY-COUNSELLOR AND MEDICAL ADVISER TO THE MINISTRY OF PUBLIC INSTRUCTION
AND MEDICINE AT BERLIN.

IN THREE VOLUMES.

VOL. III.

TRANSLATED BY
CHARLES MURCHISON, M.D., F.R.C.P.,
PHYSICIAN TO THE LONDON FEVER HOSPITAL, LECTURER ON PATHOLOGICAL ANATOMY, AND
ASSISTANT-PHYSICIAN AT THE MIDDLESEX HOSPITAL.

NEW YORK:
W.M. WOOD & CO., 27 GREAT JONES STREET.

1879.

EXPLANATION OF FRONTISPICE.

BILIARY CONCRETIONS.

Figs. 1, 2, 3. Bile-pigment crystallized from chloroform. Fig. 1. Prisms. Fig. 2. Laminae. Fig. 3. Needles.

Fig. 4. Brown pigment of bile crystallized in needles, mixed with the epithelium of the gall-bladder.

Fig. 5. Various crystalline forms of carbonate of lime from the mucous membrane of the gall-bladder.

Fig. 6. Pearl-like gall-stones.

Fig. 7. Gall-stone composed of cholesterine with a radiated structure and a calcareous shell.

Fig. 8. Crystalline gall-stone composed of cholesterine, and covered with crystals of carbonate of lime.

Fig. 9. Large concretion with a radiated nucleus of cholesterine, and a laminated shell, composed of pigment in combination with lime. This calculus caused death by obstructing the small intestine.

Fig. 10. Gall-stone composed of pure cholesterine, with a crystalline laminated structure.

Fig. 11. Radiated cut-surface of the same calculus, with a nucleus containing brown pigment.

Fig. 12. Calculus composed of cholesterine, with a cleft nucleus, radiated structure and a crust consisting of several layers.

Fig. 13. Radiated calculus of pure cholesterine, without any nucleus.

Fig. 14. Brown, flattened calculus with an amorphous appearance on section.

Fig. 15. Angular, white calculus of cholesterine, with deposits of black pigment on the corners and edges.

Fig. 16. Mulberry-shaped calculus of black pigment.

Fig. 17. Reddish-brown mulberry-shaped calculus, composed of crystals arranged in a radiated manner.

Fig. 18. White mulberry-shaped calculus, with a nucleus containing pigment.

Fig. 19. Polyhedral calculus of cholesterine with eroded angles and edges.

Fig. 20. Polyhedral greenish-brown calculus, with deep erosion and exposure of the subjacent reddish-brown layers. The two last figures illustrate the disintegration of gall-stones within the gall-bladder.

TABLE OF CONTENTS.

CHAPTER I.

	PAGE
PATHOLOGICAL NEW-FORMATIONS IN THE LIVER.—HEPATIC TUMORS.....	1
I. The cavernous tumor of the liver.....	1
II. Tubercle of the liver.....	3
III. Lymphatic new-formations.....	4
IV. Simple cysts of the liver.....	5
V. Hydatids.—Echinococci.....	6
1. Historical account.....	6
2. Anatomical description.....	7
3. Relations of the hydatids to the hepatic parenchyma.....	8
4. Changes undergone by hydatids after long duration.....	10
Their effects upon neighboring organs.....	11
Bursting in different directions.....	12
5. Symptoms.....	14
6. Duration.....	18
7. Modes of termination.....	18
8. Diagnosis.....	19
9. Complications.....	20
10. Prognosis.....	21
11. Etiology.....	21
12. Treatment.....	22
<i>a.</i> Simple puncture.....	23
<i>b.</i> Puncture, with injection of iodine, &c.....	23
<i>c.</i> Opening of the hydatid sac by caustic.....	24
<i>d.</i> Incision.....	25
The indications for operative interference.....	25
13. Illustrative cases.....	27
Appendix to section on hydatids.....	36
Compound multilocular hydatids.....	36
1. Historical account.....	36
2. Anatomical description.....	36
3. Complications.....	38
4. Etiology.....	38
5. Symptoms.....	38
6. Diagnosis.....	39
7. Mode of termination.....	39
8. Treatment.....	39
VI. Pentastoma denticulatum.....	39
VII. Cancer of the liver.....	41
1. Historical account.....	41
2. Anatomical description.....	43
Unusual varieties of cancer.....	49
<i>a.</i> Vascular cancer.—Fungus hæmatodes.....	49
<i>b.</i> Melanotic cancer and sarcomatous tumors containing pigment.....	50
<i>c.</i> Cystic cancer.....	50
<i>d.</i> Alveolar or colloid cancer.....	50
Alterations in the size, form, and consistence of the liver.....	52
Primary and secondary cancer of the liver.....	53

	PAGE
3. Etiology.....	55
<i>a.</i> Age.....	55
<i>b.</i> Sex.....	55
Other causes.....	56
4. Symptoms.....	56
Development, frequency and importance of individual symptoms.....	57
<i>a.</i> Characters presented by the liver.....	57
<i>b.</i> Jaundice.....	58
<i>c.</i> Ascites.....	58
<i>d.</i> Condition of the spleen.....	58
<i>e.</i> Digestion.....	59
<i>f.</i> Respiration.....	59
<i>g.</i> Constitution and habit of body.....	59
<i>h.</i> Hæmorrhages.....	60
5. Duration and progress.....	60
6. Prognosis.....	61
7. Diagnosis.....	61
Points of distinction from other diseases.....	61
<i>a.</i> Waxy liver.....	61
<i>b.</i> Syphilitic hepatitis.....	62
<i>c.</i> Tight-lace liver.....	62
<i>d.</i> Hydatids.....	62
<i>e.</i> Abscesses of the liver.....	62
<i>f.</i> Dilatation of the bile-ducts and gall-bladder, in consequence of occlusion of the hepatic duct and ductus choledochus.....	63
<i>g.</i> Cancer of the omentum.....	63
<i>h.</i> Cancer of the stomach.....	63
<i>i.</i> Cancer of the right kidney.....	64
<i>k.</i> Accumulation of masses of feces in the transverse colon.....	64
8. Treatment.....	64
9. Illustrative cases.....	65
A. Primary, independent cancer of the liver.....	65
B. Cancer of liver, in conjunction with cancer of the stomach.....	79
C. Cancer of Glisson's capsule.....	92
D. Cancer of liver, consequent upon cancer of the rectum.....	96
E. " " cancer of the ovaries.....	97
F. " " cancer of the brain.....	100
G. " " cancer of skin of heel.....	102
VIII. Emphysema hepatis.....	103

CHAPTER II.

DISEASES OF THE BLOOD-VESSELS OF THE LIVER, THE HEPATIC ARTERY, PORTAL VEIN AND HEPATIC VEINS.....	105
Historical account.....	105
I. Diseases of the hepatic artery.....	108
II. Diseases of the portal vein.....	113
A. Coagulation of blood in the portal vein, and adhesive inflammation of this vessel obstructing its channel.....	113
1. Causes and anatomical description.....	113
<i>a.</i> Diminished action of heart, &c.....	113
<i>b.</i> Local disturbances of the circulation in cirrhosis and chronic atrophy of liver.....	114
" " in cancer of the liver.....	117
" " in abscess of the liver.....	117
" " in dilatation of the bile-ducts.....	117
<i>c.</i> Compression of the portal vein below the liver by connective tissue.....	118
" " by tumors of various sorts.....	118
Obliteration of single branches of the portal vein and its consequences.....	121
2. Symptoms of obstruction of the portal vein.....	122
3. Diagnosis.....	123
4. Progress and duration.....	123
5. Treatment.....	124

CONTENTS.

vii

	PAGE
Dilatation of the portal vein.....	124
Calcification of the portal vein.....	125
Rupture of the portal vein.....	126
B. Suppurative inflammation of the portal vein.....	129
1. Anatomical characters.....	129
2. Etiology.....	129
a. Injury of the portal vein.....	130
b. Ulceration of the stomach and intestines.....	133
c. Suppuration of the spleen.....	136
d. Suppuration of the mesenteric glands and mesentery.....	138
e. Abscesses of the liver and diseases of bile-ducts.....	139
f. Inflammation of Glisson's capsule.....	140
3. Symptomatology of suppurative pylephlebitis.....	141
4. Origin, frequency, and diagnostic value of individual symptoms.....	142
a. Pain.....	142
b. Physical characters of liver.....	143
c. Enlargement of spleen.....	143
d. Jaundice.....	142
e. Functions of stomach and intestines.....	143
f. Fever and other general derangements.....	143
5. Diagnosis.....	144
Points of distinction from thrombosis of the portal vein.....	144
" " abscesses of liver.....	144
" " occlusion of bile-ducts by concretions.....	145
" " intermittent fever.....	145
6. Prognosis.....	145
7. Treatment.....	145
III. Diseases of the hepatic veins.....	145
A. Phlebitis hepatica adhæsiva.....	146
Observation.....	146
B. Phlebitis hepatica suppurativa.....	149
Observation.....	150

CHAPTER III.

DISEASES OF THE BILIARY PASSAGES.....	151
I. Inflammation of the biliary passages.....	152
A. Catarrhal inflammation of biliary passages.....	152
1. Anatomical description.....	152
2. Etiology.....	153
3. Symptoms and progress.....	153
4. Diagnosis.....	154
5. Treatment.....	155
6. Illustrative cases.....	156
B. Exudative inflammation of the biliary passages.....	161
Results.....	163
1. Ulceration and perforation into abdominal cavity.....	163
2. Fistulous communication with gall-bladder.....	163
3. Development of abscesses in liver.....	163
Observation.....	164
4. Propagation of inflammation to portal vein.....	166
5. Constriction and obliteration of biliary passages.....	166
Obsolescence of gall-bladder.....	167
Symptoms of exudative inflammation.....	168
Treatment of " ".....	168
Case of inflammation of gall-bladder in abdominal typhus.....	168
II. Constriction and occlusion of biliary passages.....	169
III. Dilatation of biliary passages.....	170
IV. Dilatation and droopy of gall-bladder.....	174
1. Anatomical description.....	174
2. Causes.....	174
3. Diagnosis.....	177
4. Treatment.....	178
V. Morbid growths of the biliary passages.....	179

	PAGE
VI. Foreign bodies in the biliary passages.....	180
A. Round worms in the biliary passages.....	181
B. Hydatids.....	183
C. <i>Distoma hepaticum</i> and <i>D. lanceolatum</i>	183
In the biliary passages.....	184
In the intestines.....	184
In the portal vein.....	186
Diagnosis, etiology, and treatment of distomata.....	185
The <i>distoma hæmatobium</i>	186
D. Gall-stones.....	187
1. Historical account.....	187
2. Chemical characters.....	188
a. Cholesterine.....	188
b. Bile-pigments.....	188
1. Cholepyrrhin.....	188
2. Compound of cholepyrrhin and lime.....	189
3. Cholechlorin.....	189
4. Altered bile-pigments.....	190
c. Biliary acids and their calcareous salts.....	190
1. Glycocholate of lime.....	190
2. Cholate of lime.....	190
d. Fatty acids and soaps.....	191
1. Free fatty acid.....	191
2. Compounds of fatty acids with lime.....	191
e. Mucus and epithelium.....	192
f. Uric acid.....	192
g. Inorganic matters.....	192
1. Oxides of the ponderous metals.....	192
2. Earths.....	192
3. Alkalies, potash and soda salts.....	193
3. Physical characters of gall-stones, their form, structure, &c.....	193
a. Simple homogeneous calculi.....	195
b. Compound calculi, containing a nucleus.....	195
The nucleus.....	195
The shell.....	196
The external crust.....	197
4. Mode of origin of gall-stones.....	197
5. Disintegration of ".....	200
6. Etiology.....	200
a. Age.....	200
b. Sex.....	200
c. Morbid changes in liver and biliary passages.....	201
d. Sedentary habits of life.....	201
e. Errors in diet.....	201
f. Diathesis.....	201
g. Locality.....	201
7. Situation of gall-stones.....	202
a. In the branches of the hepatic duct in the interior of the liver.....	202
b. In the hepatic duct.....	202
c. In the gall-bladder and cystic duct.....	203
d. In the ductus choledochus.....	204
8. Symptoms of gall-stones.....	204
a. In the liver.....	205
b. In the hepatic duct.....	205
c. In the gall-bladder.....	205
9. Gall-stones in the intestinal canal.....	200
10. Derangements resulting from gall-stones in intestines.....	210
11. Biliary fistulæ.....	210
12. Diagnosis of gall-stones.....	212
13. Prognosis.....	213
14. Treatment.....	213
15. Illustrative cases.....	217
Hepatic neuralgia.....	227
Observation.....	228
APPENDIX.....	231